

Luminex
complexity simplified.



**Flexible, Intuitive, and
Affordable Cytometry.**

LEARN MORE >

Guava® easyCyte™ Flow Cytometers.



Identical TCR β -Chain Rearrangements in Streptococcal Angina and Skin Lesions of Patients with Psoriasis Vulgaris

This information is current as
of October 16, 2019.

Laura Diluvio, Sigrid Vollmer, Petra Besgen, Joachim W.
Ellwart, Sergio Chimenti and Joerg C. Prinz

J Immunol 2006; 176:7104-7111; ;
doi: 10.4049/jimmunol.176.11.7104
<http://www.jimmunol.org/content/176/11/7104>

References This article **cites 44 articles**, 10 of which you can access for free at:
<http://www.jimmunol.org/content/176/11/7104.full#ref-list-1>

Why *The JI*? [Submit online.](#)

- **Rapid Reviews! 30 days*** from submission to initial decision
- **No Triage!** Every submission reviewed by practicing scientists
- **Fast Publication!** 4 weeks from acceptance to publication

**average*

Subscription Information about subscribing to *The Journal of Immunology* is online at:
<http://jimmunol.org/subscription>

Permissions Submit copyright permission requests at:
<http://www.aai.org/About/Publications/JI/copyright.html>

Email Alerts Receive free email-alerts when new articles cite this article. Sign up at:
<http://jimmunol.org/alerts>

The Journal of Immunology is published twice each month by
The American Association of Immunologists, Inc.,
1451 Rockville Pike, Suite 650, Rockville, MD 20852
Copyright © 2006 by The American Association of
Immunologists All rights reserved.
Print ISSN: 0022-1767 Online ISSN: 1550-6606.



Identical TCR β -Chain Rearrangements in Streptococcal Angina and Skin Lesions of Patients with Psoriasis Vulgaris¹

Laura Diluvio,^{*†} Sigrid Vollmer,^{*‡} Petra Besgen,^{*‡} Joachim W. Ellwart,[‡] Sergio Chimenti,[†] and Joerg C. Prinz^{2*}

Tonsillar infection with *Streptococcus pyogenes* may induce several nonsuppurative autoimmune sequelae. The precise pathogenetic mechanisms behind this clinically well-established association are still unresolved. Using TCR analysis, we sought to identify a link between streptococcal tonsillitis and the T cell-mediated autoimmune response in psoriasis. Three patients with streptococcal-induced psoriasis underwent tonsillectomy. Using size spectratyping and sequencing of TCR β -chain variable region gene (TCRBV) rearrangements, we compared the TCR usage of psoriatic skin lesions, blood, tonsils, and tonsillar T cells fractionated according to the expression of the skin addressin "cutaneous lymphocyte-associated Ag" (CLA). TCRBV-size spectratype analysis of the blood lymphocytes, tonsils, and the CLA-negative tonsillar T cells revealed largely unselected T cell populations. Instead, TCRBV gene families of the psoriatic lesions and skin-homing CLA-positive tonsillar T cells displayed highly restricted spectratypes. Sequencing of TCRBV cDNA identified various clonal TCRBV rearrangements within the psoriatic lesions that indicated Ag-driven T cell expansion. Several of these clonotypes were also detected within the tonsils and, in one of the patients, within the small subset of CLA-positive tonsillar T cells, suggesting that T cells from the same T cell clones were simultaneously present within skin and tonsillar tissue. Because after tonsillectomy psoriasis cleared in all three patients our observations indicate that T cells may connect psoriatic inflammation to streptococcal angina. They suggest that the chronic streptococcal immune stimulus within the tonsils could act as a source for pathogenic T cells in poststreptococcal disorders, and they may help to explain why eliminating this source with tonsillectomy may improve streptococcal-induced sequelae. *The Journal of Immunology*, 2006, 176: 7104–7111.

Infection with group A β -hemolytic streptococci (*Streptococcus pyogenes*) may cause several autoimmune disorders in susceptible individuals. Most prominent are acute rheumatic fever and rheumatic heart disease that constitute major causes of cardiovascular mortality worldwide (1). Other sequelae are Sydenham's chorea, poststreptococcal glomerulonephritis (2), and psoriasis vulgaris, which is the most common autoimmune disease of the human skin (3). The majority of guttate-psoriasis patients and a smaller fraction of chronic-plaque psoriasis patients experience first disease onset or relapses in direct association with streptococcal tonsillitis (4–10).

Although the close link between infection with *S. pyogenes* and the poststreptococcal sequelae is well established, the precise pathogenetic mechanisms of this association remain elusive. A common hypothesis proposes that streptococcal infection may trigger a cross-reactive autoimmune response due to epitopes shared between proteins of pathogen and host (11).

In rheumatic heart disease and in psoriasis, T cells are apparently the ultimate effectors of inflammation (11–14). In both disorders, the tonsils are the privileged site for the triggering streptococcal infection (2, 9). This indicates an intimate relationship between the infected tonsils on the one and the subsequent pathogenic immune reaction in contrast, and it suggests that a T cell-mediated immune response raised in the tonsils may subsequently become reactivated within the target organ of autoimmunity, i.e., the heart or the skin.

Proof of identical T cell clones as represented by defined TCR rearrangements within the tonsils and at the site of the ensuing autoimmune inflammation would strongly support this concept. To test this assumption we compared the TCR β -chain variable region gene (TCRBV)³ usage in skin lesions, blood, tonsils, and fractionated tonsillar T cells of three psoriasis patients who had undergone tonsillectomy because their onset of psoriasis and subsequent flares were closely linked to recurrent episodes of streptococcal sore throat. For this purpose, the TCR β -chain repertoire was amplified by PCR using 26 different TCRBV gene-specific primer pairs together with a dye-labeled TCR β -chain constant region gene (TCRBC)-specific primer. The PCR products covered the CDR3 which carries the Ag specificity of the TCR β -chain and differs in length according to the particular TCR-VDJ rearrangement (15). Fragment lengths analysis of the amplified TCRBV rearrangements on a genetic sequencer yields spectratypes with peaks spaced by three nucleotides, where each peak represents

*Department of Dermatology, Ludwig-Maximilians-University of Munich, Munich, Germany; [†]Department of Dermatology, University of Rome "Tor Vergata", Rome, Italy; and [‡]Institute for Molecular Immunology, GSF-Research Center for Environment and Health, Munich, Germany

Received for publication November 29, 2005. Accepted for publication March 14, 2006.

The costs of publication of this article were defrayed in part by the payment of page charges. This article must therefore be hereby marked *advertisement* in accordance with 18 U.S.C. Section 1734 solely to indicate this fact.

¹ This work was supported by the Sonderforschungsbereich 571 of the Deutsche Forschungsgemeinschaft. L.D. was the recipient of a grant of the German Academic Exchange Service.

² Address correspondence and reprint requests to Dr. Joerg C. Prinz, Department of Dermatology, University of Munich, Frauenlobstrasse 9-11, D-80337 Munich, Germany. E-mail address: joerg.prinz@med.uni-muenchen.de

³ Abbreviations used in this paper: TCRBV, TCR β -chain variable region gene; TCRBC, TCR β -chain constant region gene; ASLO, anti-streptolysin O; DNase B, antideoxyribonuclease B; PASI, psoriasis area and severity index; CLA, cutaneous lymphocyte-associated Ag; PPP, palmoplantar pustulosis; EAE, experimental autoimmune encephalitis.

TCR β -chain rearrangements of the same length (16). A restricted usage of TCRBV rearrangements with a particular length of the CDR3 may denote clonal T cell expansions. The cDNA of TCRBV gene families with such evidence for clonal T cell selection within the psoriatic skin lesions was cloned and sequenced, and the TCR clonotypes identified by these means were then traced in the corresponding blood and tonsil samples. Molecular tracking of particular T cells by TCR analysis has been used as a powerful tool to dissect the pathomechanism of autoimmune diseases (17–20). By this approach, we now obtained first evidence that the skin-associated lesional psoriatic T cell clones may be simultaneously present within the tonsils of patients with streptococcal-induced psoriasis. Because all three patients experienced a lasting remission of their psoriasis following tonsillectomy our data propose that T cells could represent a functional link between streptococcal angina and psoriasis. They furthermore may help to explain why eliminating this source of the pathogenic T cells by tonsillectomy may improve the course of the poststreptococcal sequelae.

Materials and Methods

Patients

Three patients with histologically proven psoriasis voluntarily participated in the study which was approved by the local ethics committee. They gave written informed consent. Streptococcal infection was assessed during acute flares of tonsillitis by pharyngeal swabbing and standard methods of bacterial isolation, and by determination of anti-streptolysin O (ASLO) and anti-deoxyribonuclease B (DNase-B) serum-Ab titers (normal range <200 IU/ml each). Lesional skin biopsies and blood samples were obtained on the same day. Tonsillectomy was performed within 1 wk after the skin biopsy. The need for tonsillectomy had already been determined by otorhinolaryngology. After tonsillectomy, patients were followed for more than three years. The last control of disease activity was performed before the submission of the manuscript. Psoriasis severity was determined by the psoriasis area and severity index (PASI), which is a widely used scoring system to assess psoriasis severity in clinical trials (21).

Tissue specimens

PBL were prepared from heparinized venous blood by Ficoll density-gradient centrifugation. For the preparation of RNA PBL, skin biopsies and tonsillar tissue fragments were minced in guanidinium isothiocyanate buffer using a tissue homogenizer essentially as described previously (22–24).

To obtain single-cell suspensions, small pieces of the tonsils were repeatedly passed through a fine steel mesh using a plunger. The suspension was broken into single cells by repeatedly aspirating it through a fine needle using a syringe.

Sorting of tonsillar T cells

Tonsillar T cells were stained with a PE-labeled monoclonal CD3 Ab (V5T-CD03.05) and a FITC-conjugated mAb specific for the cutaneous lymphocyte-associated Ag (CLA) (HECA-452) (all from BD Biosciences). FACS analysis and sorting of 1×10^7 tonsillar T cells were performed on a Moflo modular flow cytometer (DakoCytomation).

Preparation of cDNA and analysis of the TCRBV repertoire by spectratyping

Extraction of RNA, preparation of cDNA, and amplification of the TCRBV gene repertoire have been described previously (22–24). For TCRBV gene repertoire analysis, cDNA was amplified using a common 6-FAM-labeled TCRBC 3' primer in conjunction with each one of 26 different 5' TCRBV gene family primers. cDNA was amplified for 35 PCR cycles as described. After adding a standard size marker (500 TAMRA; Applied Biosystems), cDNA-fragment length analysis was performed using an ABI Prism 310 Genetic Analyzer and GeneScan Analysis Software 3.1 and Sequencing Analysis Software 3.4 according to the manufacturer's protocol (Applied Biosystems).

Interpretation of spectratypes

Due to the recombination events during TCR generation, the length of the TCR amplicons varies. In unselected T cell populations, CDR3-length analysis produces ~5–10 identifiable peaks spaced by three nucleotides,

with fluorescence intensity following a quasi-Gaussian distribution (25, 26). Each peak represents TCR rearrangements with an identical number of coding nucleotides (16).

The spectratype patterns were compared with each other visually. A regular spectratype profile was defined as having an approximate Gaussian bell-shaped distribution, showing a largely symmetrical profile with the highest fluorescence intensity in the middle. If discrete peaks differed from the Gaussian profile, or if particular peaks were missing the spectratype was defined as skewed. Skewing was interpreted as a selection of TCRBV gene rearrangements of a particular length that suggested clonal TCR rearrangements (16).

Cloning and sequencing of PCR products

Cloning of PCR products of lesional psoriatic TCRBV gene families was done by TA cloning (TA Cloning kit dual promoter, using the pCRII vector in One Shot TOP10F competent cells; Invitrogen Life Technologies) according to the manufacturer's protocol. Negative control reactions without cDNA were set up with each primer pair.

Plasmid DNA was sequenced using the ABI BigDye terminator cycle sequencing kit and an ABI Prism 310 genetic analyzer according to the manufacturer's advice (Applied Biosystems). In the manuscript, TCR rearrangements are given as deduced amino acid sequence of the CDR3. Repetitive TCR rearrangements were defined as clonotypes.

For the select amplification and sequencing of the clonal psoriatic TCRBV3 and BV13S2 rearrangements of patient 1, the following primer pairs were designed: BV3, 5'-C AGC AGT TCG TCC GGG AC-3'; BJ1.5, 5'-GAG TCG AGT CCC ATC ACC-3'; BV13S2, 5'-GCC AGC TCC AGG AGG GAC-3'; BJ 2.2, 5'-CAG CCT AGA GCC TTC TCC-3'.

Results

Long-term remission of moderate to severe psoriasis following tonsillectomy indicates a functional relationship between streptococcal angina and psoriatic skin inflammation

Three patients with chronic plaque-psoriasis were included into the study (Table I). They had a history of treatment-refractory psoriasis of 1.5, 6, or 10 years, and onset and subsequent flares of their psoriasis had been closely related to recurrent episodes of streptococcal angina. All three patients had streptococcal colonization of the tonsils proven by bacterial cultures and elevated titers of anti-streptococcal serum Abs. Because of the clinically obvious link between streptococcal sore throat and psoriasis flares the patients underwent tonsillectomy. The severity of psoriasis at the time of tonsillectomy was determined by the PASI that ranges from 0 (no psoriasis) to 72 (mathematical maximum) (21). Patient 1 had a PASI of 17, patient 2 of 11.4, and patient 3 of 22.8 which is equivalent to moderate to severe psoriasis. In all three patients, tonsillectomy was followed by a long-term remission of psoriasis with a complete clearance of skin symptoms now exceeding 3 years. This obvious correlation between removal of the tonsils and recovery from psoriasis supported that the streptococcal angina had acted as a trigger for psoriasis in these patients, and it confirmed former observations that tonsillectomy may improve the course of streptococcal-driven psoriasis (27–29).

The three patients had allowed the use of pieces of their tonsils for experimental analysis, and they provided a blood sample and a lesional psoriatic biopsy that were obtained within the week before tonsillectomy.

Psoriatic skin lesion but not blood or tonsils show a highly restricted TCR usage

Several recent studies have demonstrated that psoriatic inflammation is promoted by a highly conserved clonal T cell response (22, 23, 30, 31). We therefore sought to examine the suspected relationship between streptococcal angina and psoriatic inflammation on the level of T cells. To identify the disease-related T cell clones within the psoriatic skin lesions of our patients, we determined the

Table I. Patient data^a

	Patient 1	Patient 2	Patient 3
Clinical manifestation	Recalcitrant type-1 nonpustular chronic plaque psoriasis with guttate flares		
Age at psoriasis onset	20 years	19 years	27 years
Angina at onset	Yes	Yes	Not known
Flares related to angina	Yes	Yes	Yes
Disease duration at tonsillectomy	1.5 years	10 years	6 years
PASI at tonsillectomy	17	11.4	22.8
Serum Ab titers			
ASLO (normal < 200 IU/ml)	375 IU/ml	209 IU/ml	1048 IU/ml
DNase B (normal < 200 IU/ml)	281 IU/ml	253 IU/ml	598 IU/ml
Bacterial culture from tonsils	<i>S. pyogenes</i>	<i>S. pyogenes</i>	<i>S. pyogenes</i>
Skewed lesional psoriatic TCRBV spectratypes with prominent peaks	TCRBV3, 4, 6, 7, 13S2, 21	TCRBV3, 9, 13S2, 21	TCRBV2, 3, 6, 7, 9, 13S1, 13S2, 19, 21
TCRBV chosen for sequence analysis	TCRBV3, 13S2	TCRBV13S2	TCRBV3, 13S2, 21
% CLA-positive tonsillar T cells	4.4	4.5	5.0
Effect of tonsillectomy	Complete remission of psoriasis exceeding a 3-year observation period (PASI 0)		

^a Three patients underwent tonsillectomy because of streptococcal angina-induced psoriasis as confirmed by clinical course, bacterial cultures from tonsillar swabs, streptococci-specific serum-Ab titers, and long-term remission of psoriasis after tonsillectomy. Spectratyping of TCRBV rearrangements in skin lesions, blood, tonsils, and fractionated tonsillar T cells identified TCRBV families with highly selected TCR rearrangements of identical size in the psoriatic skin lesions. These TCRBV families were chosen for further analysis by cloning and sequencing of TCR rearrangements from skin, blood, and tonsils. PASI, psoriasis area and severity index; ASLO, anti-streptolysin O; DNase B, anti-deoxyribonuclease B; CLA, cutaneous lymphocyte-associated Ag.

TCR usage of the lesional psoriatic biopsies by β -chain CDR3-length spectratype analysis and compared it to the TCR spectratypes of the blood lymphocytes and tonsils. For this purpose, TCRBV cDNA was amplified from the different specimens by PCR using TCRBV gene-specific primer pairs. The fragment length of the amplicons was analyzed on a genetic sequencer.

In all three patients, PBL showed a predominance of quasi-Gaussian repertoire β -chain lengths in most TCRBV families that reflected largely unselected T cell populations. In general, the tonsillar spectratypes showed similar numbers of peaks as the corresponding blood spectratypes. Only occasionally did they deviate from the Gaussian distribution of TCR lengths or from the blood profiles (Figs. 1–3).

Spectratypes from psoriatic skin lesions of the three patients showed a highly restricted pattern that clearly differed from the spectratypes of blood and tonsils. Only in a small number of TCRBV gene families could PCR amplify sizeable TCR rearrangements from the skin lesions (Table I). They were TCRBV3, 4, 6, 7, 13S2, and 21 in patient 1 (Fig. 1A); TCRBV3, 9, 13S2, and 21 in patient 2 (Fig. 2A); and TCRBV2, 3, 6, 7, 9, 13S1, 13S2, 19, and 21 in patient 3 (Fig. 3A). These spectratypes consisted of only a few selectively expanded peaks, which indicated a disease-asso-

ciated selection of T cells with a particular length of the TCR rearrangements (16). For the remaining skin-derived TCRBV gene families, TCR rearrangements could hardly be amplified. Representative examples of these unproductive spectratypes are given in Figs. 1B, 2B, and 3B for the three patients.

Sequencing identifies clonal TCRBV gene rearrangements in the psoriatic skin lesions that are simultaneously present within the tonsils

TCRBV gene spectratypes with a particularly strong evidence for clonal T cell expansion within the psoriatic skin lesions were chosen for molecular analysis of the TCR rearrangements. They were TCRBV3 (patients 1 and 3), BV13S2 (patients 1–3), and BV21 (patient 3) (Figs. 1A, 2A, and 3A). cDNA of these TCRBV gene families was amplified from the skin lesions and the corresponding blood and tonsil samples, randomly cloned and sequenced.

In patient 1, nucleotide-sequence analysis revealed that the lesional psoriatic TCRBV3 rearrangements (Table II) were dominated by a particular clonotype (SSGTGY, Table II), which represented 12 of 13 analyzed TCR sequences. This particular TCR rearrangement was detected twice among 40 tonsillar TCRBV3

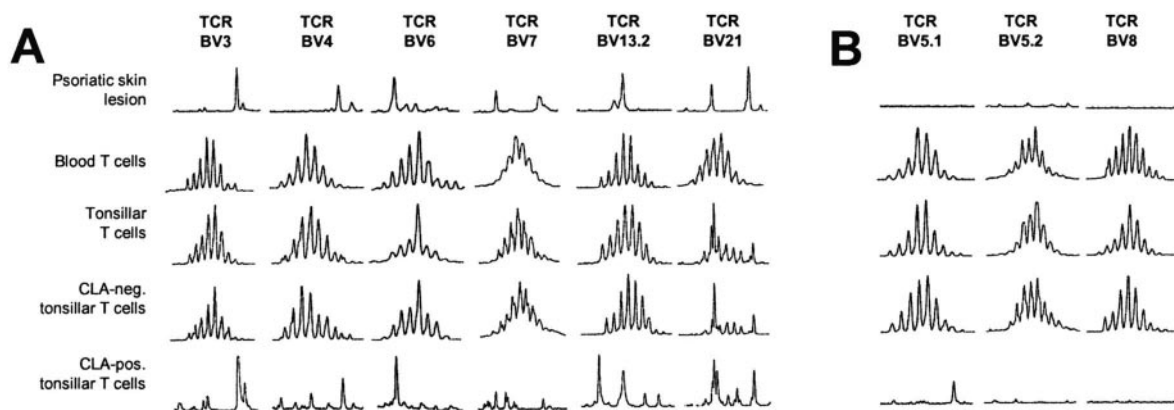
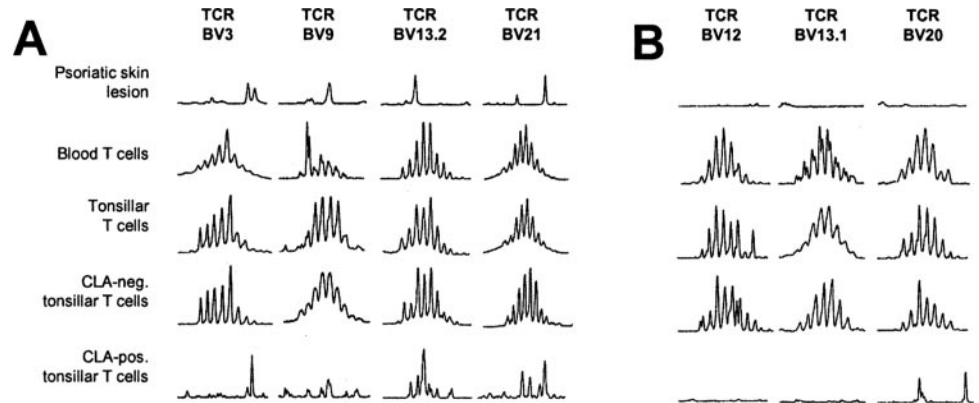


FIGURE 1. Spectratypes of TCRBV gene rearrangements of patient 1. CDR3 spectratypes of the TCRBV gene families selected within the psoriatic skin lesion (A), and of three exemplarily chosen TCRBV gene families largely absent from the psoriatic skin lesion (B). The spectratypes of TCRBV gene families amplified from the psoriatic skin lesions and the CLA-positive tonsillar T cells reveal a bias for TCRBV rearrangements with particular lengths of the CDR3 and thus suggest the presence of oligoclonal T cell expansions in these samples, while the spectratypes from PBL, tonsil, and CLA-negative tonsillar T cells show largely Gaussian-like distributions. TCR β -chain cDNA was amplified by PCR using 26 TCRBV gene-specific primer pairs. The fragment length of the PCR products of each TCRBV gene family was analyzed on a genetic sequencer, yielding spectratypes with peaks spaced by three nucleotides. Each peak represents TCR β -chain rearrangements of the same length.

FIGURE 2. Spectratypes of TCRBV gene rearrangements of patient 2. CDR3 spectratypes of the TCRBV gene families selected within the psoriatic skin lesion (A), and of three exemplarily chosen TCRBV gene families largely absent from the psoriatic skin lesion (B). For explanation, refer to the legend of Fig. 1.



rearrangements, but not among 45 polyclonal blood rearrangements. The lesional psoriatic BV13S2 rearrangements of patient 1 contained two major clonotypes, QH (54 of 79 rearrangements) and SRRDMN (15 of 79). The latter was identified 11 times in 77 otherwise nonrepetitive tonsillar BV13S2 rearrangements, but not in 56 polyclonal blood BV13S2 rearrangements (Table II). One particular TCRBV13S2 rearrangement was identified each once in blood and tonsils while it was not detected with the skin lesion.

In patient 2, psoriatic TCRBV13S2 rearrangements contained three major TCR clones coding for the amino acid sequence RSL LAGTV (24 of 62), SPTSGI (19 of 62), and SPGLGGRAVD (18 of 62). The latter was detected 10 times in 87 otherwise polyclonal rearrangements but not in 40 polyclonal blood rearrangements (Table II). One TCRBV13S2 rearrangement was identical in blood and tonsils (sequence not shown).

TCRBV3, BV13S2, and BV21 rearrangements from psoriatic skin lesions of patient 3 were less clonal. This corresponded to broader spectratypes, with more peaks present than in the skin spectratypes of the other patients, but still less than in the corresponding blood sample or tonsil (Fig. 3A). All three TCRBV gene families contained TCR rearrangements that were also identified within the tonsils, but not in the blood (Table II), while TCR rearrangements in blood and tonsils were completely different.

Thus, as suggested by the TCR spectratypes, sequencing of TCR β -chain rearrangements identified clonally expanded TCR rearrangements in the skin lesion of the three patients. Most interestingly, several of these TCR rearrangements were also observed within the tonsils. Therefore, our data suggest that T cells belonging to the same T cell clones may simultaneously have been

present in psoriatic skin lesions and tonsils, while they were absent from the corresponding blood samples. Instead, according to the molecular analysis of TCR rearrangements TCR usages in blood and skin or blood and tonsils were largely exclusive.

Skin homing tonsillar T cells have skewed TCR repertoires and may contain the lesional psoriatic T cell clones

A T cell dependent relationship between streptococcal angina and psoriatic skin inflammation would require that the tonsillar T cells are capable of entering the skin and express particular skin homing receptors, namely the CLA (32). In psoriasis patients CLA-positive T lymphocytes preferentially migrate to the skin (33). Therefore, we wondered whether the tonsils of the psoriasis patients contained T cells expressing this skin-selective homing receptor, whether these CLA-positive T cells differed in their TCR usage from the CLA-negative tonsillar T cells, and whether within the tonsils the lesional psoriatic clonotypes might be selectively assigned to the fraction of CLA-positive tonsillar T cells.

For this purpose, single-cell suspensions were prepared from pieces of the tonsils, stained with fluorescent CD3 and CLA mAbs and sorted into CLA-positive and CLA-negative T cell populations by FACS.

In the three patients, a small fraction of 4.4, 4.5, or 5% of the tonsillar T cells expressed the CLA molecule (Table I). The sorted fractions were subjected to TCR spectratyping. Although the spectratypes of the CLA-negative T cells largely resembled those of the unsorted tonsillar T cells, the TCRBV gene families of the CLA-positive T cells showed highly restricted spectratypes that

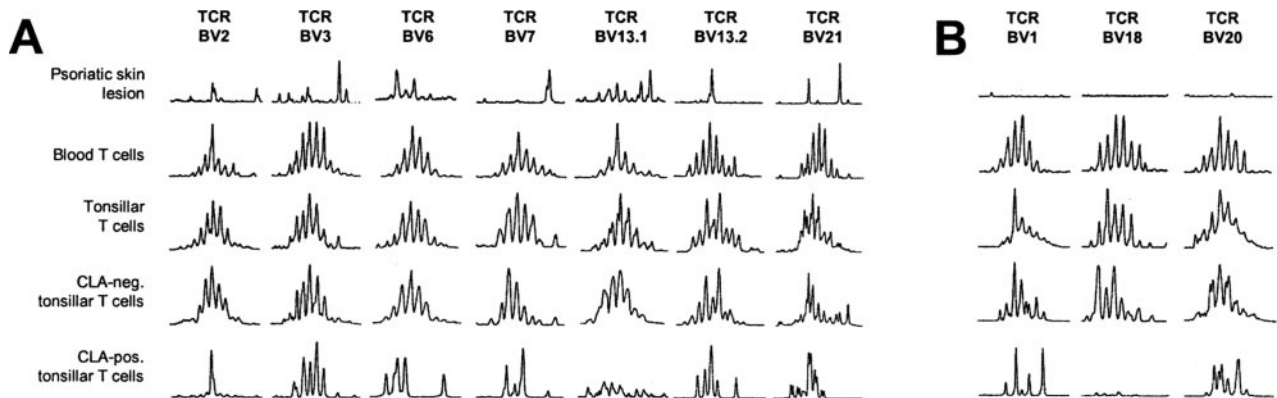


FIGURE 3. Spectratypes of TCRBV gene rearrangements of patient 3. CDR3 spectratypes of the TCRBV gene families selected within the psoriatic skin lesion (A), and of three exemplarily chosen TCRBV gene families largely absent from the psoriatic skin lesion (B). For explanation, refer to the legend of Fig. 1.

Table II. Amino acid and nucleotide sequences of identical TCRBV-gene rearrangements in psoriatic skin lesions and tonsils^{a,b}

Patient	TCRBV	BV ^c	CDR3 ^d NDN	BJ ^e	Skin ^e	Tonsils	Blood	CLA Positive	CLA Negative
1	3	C A S S	S S G T G Y	Q P Q H F	1.5	2/40	0/45	25/25	0/29
		tgt gcc agc agt	tcg tcc ggg aca gga tat	cag ccc cag cat ttt	12/13				
		C A S S	S R R D M N	T G E L F F	2.2	15/79	0/56	11/33	0/24
2	13S2	tgt gcc acc	tcc agg agg gac atg aac	acc ggg gag gtc ttt ttt	2.1	10/87	0/40	ND	ND
		C A S S Y	S P G L G G R A V D	E Q F F F	2.1	2/37	0/11	ND	ND
		tgt gcc agc agt tac	tcg cct ggg ttg ggc ggg agg gcc gtc gat	gag cag ttc ttc	2.2	1/37	0/11	ND	ND
3	3	C A S S	S Y G V G N	N E Q F F	1.4	2/77	0/11	ND	ND
		tgt gcc agc agt	tcc tat ggg gtg ggg aac	aat gag cag ttc ttc	1.1	1/37	0/11	ND	ND
		C A S S	P G E	T G E L F F	1.5	1/74	0/45	ND	ND
13S2	3	ccg gga gaa	ccg gga gaa	acc ggg gag ctg ttt ttt	2.2	1/77	0/45	ND	ND
		C A S S	S R D S L A V	E K L F F	1.4	1/37	0/11	ND	ND
		tgt gcc agc agt	tcg agg gac agc ctg gca gtc	gaa aaa ctg ttt ttt	1.1	1/37	0/45	ND	ND
21	3	C A S S	T N R G E P	E A F F	1.5	1/60	0/45	ND	ND
		tgt gcc agc agt	Aca aac agg ggg gag cct	gaa gct ttc ttt	2.2	3/74	0/45	ND	ND
		C A S S Y	S P V Q G R S Y	S N Q P Q H F	1.2	1/74	0/45	ND	ND
21	3	tgt gcc agc agt tac	tcc ccg gta cag gga cgg tct tat	agc aat cag ccc cag cat ttt	2.1	1/60	0/45	ND	ND
		C A S S	E Q G S L A	G E L F F	1.1	1/60	0/45	ND	ND
		tgt gcc agc agc	gag cag ggg tcg ttg gcc	ggg gag ctg ttt ttt	1.2	1/60	0/45	ND	ND
21	3	C A S S	S P Q G S G	Y G Y T F	2.1	1/60	0/45	ND	ND
		tgt gcc agc agt tac	agc cct cag ggg tcc ggc	tat ggc tac acc ttc	1.1	6/79	0/60	ND	ND
		C A S S	ttt tcg ggt aac	aat gag cag ttc ttc	1.6	6/79	0/60	ND	ND
21	3	tgt gcc agc agc	ggg acc	E A F F	2.3	2/79	0/60	ND	ND
		C A S S	S A G R G D	S P L H F	2.7	1/79	0/60	ND	ND
		tgt gcc agc agc	tcc gcy ggt agg ggg gac	gaa gct ttc ttt	1.1	1/79	0/60	ND	ND
21	3	C A S S	L G T G E	tca ccc ctc cac ttt	1.1	1/79	0/60	ND	ND
		tgt gcc agc agc	ctc gga acg gga gaa	T D T Q Y F	1.1	1/79	0/60	ND	ND
		C A S S L	G G Q V	aca gat acg cag tat ttt	1.1	1/79	0/60	ND	ND
21	3	tgt gcc agc agc tta	ggg ggc caa gtc	Y E Q Y F	1.1	1/79	0/60	ND	ND
		C A S S L	G E	tac gag cag tac ttc	1.1	1/79	0/60	ND	ND
		tgt gcc agc agc tta	ggc gag	N T E A F F	1.1	1/79	0/60	ND	ND
21	3	tgt gcc agc agc	ggc gag	aac act gaa gct ttc ttt	1.1	1/79	0/60	ND	ND

^aFor molecular analysis, cDNA of the TCR rearrangements was amplified by PCR from the different samples, randomly cloned, and sequenced. Repetitive TCR rearrangements were defined as clonotypes. Several of the lesional psoriatic clonotypes were also identified within the tonsils but not in the blood of psoriasis patients that had undergone tonsillectomy because of streptococcal angina-induced psoriasis. By the use of CDR3-specific primer pairs in patient 1, they could be selectively assigned to the fraction of tonsillar T cells that express the skin-homing receptor CLA.

^bTCR rearrangements are given as deduced amino acid sequence (one letter code) and nucleotide triplets.

^cFlanking BV and BJ region; BV: β -chain variable gene element; BJ: β -chain joining gene element.

^dCDR3, determined according to Rock et al. (44).

^eFrequency is given as identical TCR rearrangements/number of TCR rearrangements sequenced.

usually were dominated by only a few peaks (Figs. 1–3). This indicated that other than the CLA-negative T cells, the CLA-positive T cells were subjected to a profound T cell selection pressure within the tonsils.

In patient 1, the TCRBV3 and BV13S2 spectratypes of the CLA-positive tonsillar T cells displayed particular evident overlaps with the corresponding lesional psoriatic spectratype (Fig. 1A). Therefore, this patient was exemplarily chosen to examine whether the clonal TCRBV3 and BV13S2 rearrangements of the psoriatic skin lesions might be identified within the fraction of CLA-positive tonsillar T cells. To increase the sensitivity of the assay and to corroborate an exclusive assignment to either the CLA-positive or CLA-negative T cell subset, we designed PCR primer pairs specific for the TCRBV-BJ gene recombination. With this approach, both the TCRBV3 (SSGTGY) and the BV13S2 rearrangement (SRRDMN) could be amplified from the CLA-positive tonsillar T cell fraction, while they were definitely absent from the CLA-negative T cells (Table II). These findings suggest that, within the tonsils, the lesional psoriatic T cell clones may belong to the CLA-positive T cell fraction and represent skin-homing T cells.

Discussion

Psoriasis vulgaris is a usually lifelong persisting HLA-associated inflammatory skin disease. It is characterized by an excessive hyperproliferation of keratinocytes which leads to heavily scaling reddish plaques that may cover large areas of the skin. According to current concepts, psoriasis represents a T cell-mediated autoimmune disease (11, 14, 34). The presence of highly selected oligoclonal T cell populations within affected skin supports that Ag-specific T cell activation is a major pathogenetic mechanism of psoriatic inflammation. This Ag-specific T cell response is stable and dominant. The same T cell clones were identified in repeated biopsies taken over periods >3 years from different skin lesions, while they were absent from nonaffected skin or blood of the same patient (22, 23, 30, 31). The obvious continuity and selectivity of the psoriatic T cell response may be used to decipher the psoriatic immune cascade by tracking the pathogenic T cell clones. We chose this approach to examine the relationship between streptococcal angina and autoimmune sequelae and characterized the TCR usage in skin, blood and tonsils of three psoriasis patients with streptococcal-driven psoriasis.

Several aspects of our results may contribute to the understanding of the autoimmune pathomechanisms in streptococcal-induced psoriasis and other T cell-mediated poststreptococcal disorders. Spectratyping and sequence analysis of TCR β -chain cDNA confirmed by the identification of repetitive TCRBV gene rearrangements that the lesional psoriatic immune response is dominated by clonal T cell expansions. Interestingly, several of these TCRBV gene families, namely TCRBV2, 3, 6, 9, and 13S1, had already been identified in former studies to contain disease-relevant T cell clones (22, 24, 30). The lesional psoriatic TCR clonotypes stood clearly out from the otherwise largely polyclonal TCR distributions in blood and tonsils, emphasizing Ag-driven T cell stimulation in the skin of our patients. Thus, psoriasis seems to behave like other T cell-mediated autoimmune disorders for which it is well established that, following activation by Ags, the pathogenic T cells use a limited number of TCR chains in the target organ (35).

By tracking the lesional psoriatic TCR rearrangements in blood and tonsils, our data now suggest for the first time that the lesional psoriatic T cell clones may simultaneously be present within the tonsils of patients whose psoriasis is driven by streptococcal angina. Several of the lesional TCR β -chain clonotypes were iden-

tified among the tonsillar TCRBV gene rearrangements where they represented up to 14% of the rearrangements analyzed, while they were not detected in the corresponding blood sample. This is particularly remarkable because diversity is one of the fundamental principles in the immune system and is achieved by the formation of an enormously high number of structurally different TCR molecules (15). Because thymocytes undergo proliferation between β -chain and α -chain rearrangement it would, however, be possible that the same TCR β -chain combines with different α -chains and thus belongs to different T cell clones (36, 37). Still, the simultaneous selection of several TCRBV gene rearrangements within both psoriatic skin lesions and tonsils, their obvious absence from blood, as well as the long-term remission of psoriasis after tonsillectomy support that the identical TCRBV gene rearrangements in psoriatic skin lesions and tonsils may actually reflect the occurrence of T cells from the same T cell clones at these two distinct sites.

If we assume that, like in other autoimmune disorders, the clonal T cell expansion is a consequence of Ag-specific stimulation, then our data suggest that similar antigenic stimuli could have mediated a selection of T cells from the same pathogenic T cell clones within the psoriatic skin lesions and the tonsils. Because of the lack of an appropriate animal model of infection-induced psoriasis, it will be difficult to examine whether the T cells actually spread from the angina to the integument. Because the streptococcal trigger precedes psoriasis onset by at least 10–14 days, we would speculate that the pathogenic psoriatic T cells become activated first in the tonsils and then enter into the skin. A similar sequence of events in the induction of organ-specific autoimmunity has recently been demonstrated in an animal model of experimental autoimmune encephalitis (EAE). As shown by CDR3-spectratype analysis and TCR sequencing, induction of EAE by immunization with myelin basic protein in Lewis rats induced expansion of the pathogenic T cell clone first in the lymphoid organs from where the activated encephalitogenic T cells then disseminated and reached the spinal cord before the onset of EAE (38).

To enter the skin, T cells require skin-homing receptors such as CLA. A special relevance of our findings for streptococcal-induced psoriatic skin inflammation is therefore emphasized by the observation that in patient 1 the clonal psoriatic TCR β -chain rearrangements could be selectively assigned to the small subset of CLA-positive tonsillar T cells. Using primer pairs specific for the rearrangement site, the lesional psoriatic TCR clonotypes could only be amplified from the fraction of the sorted CLA-positive but not the CLA-negative tonsillar T cell fraction. Thus, within the tonsils the lesional psoriatic T cell clones may represent skin-homing T cells.

As determined by FACS analysis of cell suspensions prepared from the tonsils of the three patients, CLA was expressed by 4–5% of the tonsillar T cells. This frequency was lower than in tonsils of patients with palmoplantar pustulosis (PPP), another inflammatory skin disease found in direct association with streptococcal angina. In these patients, between 7.9 and 18.9% of the tonsillar T cells expressed CLA, while non-PPP patients had a frequency of 4.2–4.6 CLA-positive tonsillar T cells (39). In the PPP patients, CLA expression on T cells could be experimentally reproduced by stimulation of tonsillar T cells with crude streptococcal lysates via the induction of TGF- β . It is well known that CLA may be induced on memory T cells by various stimuli such as Th1-polarizing cytokines or streptococcal or staphylococcal superantigens (40, 41). Accordingly, streptococcal angina might prime and select tonsillar T cells to

migrate into the skin either by the particular cytokine environment of infection-induced inflammation, or by streptococcal superantigens, as suggested recently (42). Superantigens would induce a polyclonal expansion of T cells sharing particular TCRBV regions. Because the clonal representation of some of the lesional psoriatic TCR clonotypes within the tonsils reached up to 14% of the analyzed rearrangements a relevant role of superantigens in streptococcal angina appears unlikely. Furthermore, unlike the CLA-negative tonsillar T cell fraction the CLA-positive tonsillar T cells displayed highly skewed TCR spectratypes. None of them had a Gaussian-like polyclonal distribution but all of them showed restricted fragment length distributions compatible with oligoclonal T cell expansions. Thus, within the tonsils the CLA-positive T cells were apparently subjected to an Ag-specific selection rather than superantigen-mediated stimulation.

According to these observations, T cells may represent the functional link between streptococcal tonsillitis and psoriatic inflammation. They suggest that streptococcal angina might prime and select tonsillar T cells to migrate into the skin, where they become reactivated to expand clonally and promote the formation of psoriatic skin lesions. This assumption is strongly supported by the course of psoriasis after tonsillectomy. Despite a history of permanently active, recalcitrant psoriasis of 1.5, 6, or 10 years, tonsillectomy was followed by a long-term remission of psoriatic skin inflammation >3 years in all three patients. A similar beneficial role of tonsillectomy on the course of psoriasis has been documented in several case reports and retrospective or prospective clinical trials (27–29). Furthermore, a patient with poststreptococcal arthritis who improved after tonsillectomy had identical TCR rearrangements in tonsils and inflamed joints (43). Thus, it seems that tonsillectomy may cut off the supply for the pathogenic psoriatic T cell clones when streptococcal angina is the triggering event. Our results therefore support that streptococcal angina may serve as a continuous source of the pathogenic psoriatic T cells in streptococcal-induced psoriasis, and they provide a factual basis for tonsillectomy as a therapeutic rationale in autoimmune disorders following streptococcal angina.

Taken together, our findings shed light on the pathogenetic relationship between streptococcal angina and autoimmune sequelae. They propose that in T cell-mediated poststreptococcal disorders, the ultimate effectors of autoimmune inflammation may be derived from the tonsils, and they explain why this link may be more accessible to treatment than the streptococcal infection itself. Accordingly, they might affect both the understanding and handling of streptococcal-induced autoimmunity.

Acknowledgments

We are grateful to Prof. Walter Burgdorf for discussing the manuscript

Disclosures

The authors have no financial conflict of interest.

References

- Olivier, C. 2000. Rheumatic fever—is it still a problem? *J. Antimicrob. Chemother.* 45: 13–21.
- Cunningham, M. W. 2000. Pathogenesis of group A streptococcal infections. *Clin. Microbiol. Rev.* 13: 470–511.
- Lebwohl, M. 2003. Psoriasis. *Lancet* 361: 1197–114.
- Nordlind, K. 1955. Significance of infections in origin of psoriasis. *Acta Rheumatol. Scand.* 1: 135–144.
- Whyte, H. J., and R. D. Baughman. 1964. Acute guttate psoriasis and streptococcal infection. *Arch. Dermatol.* 89: 350–356.
- Tervaert, W. C., and H. Esseveld. 1970. A study of the incidence of haemolytic streptococci in the throat in patients with psoriasis vulgaris, with reference to their role in the pathogenesis of this disease. *Dermatologica* 140: 282–290.
- Telfer, N. R., R. J. G. Chalmers, K. Whale, and J. Colman. 1992. The role of streptococcal infection in the initiation of guttate psoriasis. *Arch. Dermatol.* 128: 39–43.
- Gudjonsson, J., A. M. Thorarinsson, B. Sigurgeirsson, K. G. Kristinsson, and H. Valdimarsson. 2003. Streptococcal throat infections and exacerbation of chronic plaque psoriasis: a prospective study. *Br. J. Dermatol.* 149: 530–534.
- Mallbris, L., P. Larsson, S. Bergqvist, E. Vingard, F. Granath, and M. Stahle. 2005. Psoriasis phenotype at disease onset: clinical characterization of 400 adult cases. *J. Invest. Dermatol.* 124: 499–504.
- Weisenseel, P., B. Laumbacher, P. Besgen, D. Ludolph-Hauser, T. Herzinger, M. Roecken, R. Wank, and J. C. Prinz. 2002. Streptococcal infection distinguishes different types of psoriasis. *J. Med. Genet.* 39: 767–768.
- Prinz, J. C. 2004. Disease mimicry: a pathogenetic concept for T cell-mediated autoimmune disorders triggered by molecular mimicry? *Autoimmun. Rev.* 3: 10–15.
- Guilherme, L., and J. Kalil. 2002. Rheumatic fever: the T cell response leading to autoimmune aggression in the heart. *Autoimmun. Rev.* 1: 261–266.
- Valdimarsson, H., B. S. Baker, I. Jonsdottir, and L. Fry. 1986. Psoriasis: a disease of abnormal keratinocyte proliferation induced by T lymphocytes. *Immunol. Today* 7: 256–259.
- Nickoloff, B. J., and F. O. Nestle. 2004. Recent insights into the immunopathogenesis of psoriasis provide new therapeutic opportunities. *J. Clin. Invest.* 113: 1664–1675.
- Davis, M. M., and P. J. Bjorkman. 1988. T cell antigen receptor genes and T cell recognition. *Nature* 334: 395–402.
- Pannetier, C., J. Even, and P. Kourilsky. 1995. T cell receptor diversity and clonal expansions in normal and clinical samples. *Immunol. Today* 16: 176–181.
- Wucherpfennig, K. W., and D. A. Hafler. 1995. A review of T cell receptors in multiple sclerosis: clonal expansion and persistence of human T cells specific for an immunodominant myelin basic protein peptide. *Ann. NY Acad. Sci.* 756: 241–258.
- Madsen, L. S., E. C. Andersson, L. Jansson, M. Krogsgaard, C. B. Andersen, J. Engberg, J. L. Strominger, A. Svejgaard, J. P. Hjorth, R. Holmdahl, et al. 1999. A humanized model for multiple sclerosis using HLA-DR2 and a human T cell receptor. *Nat. Genet.* 23: 343–347.
- Hofbauer, M., S. Wiesener, H. Babbe, A. Roers, H. Wekerle, K. Dormair, R. Hohlfield, and N. Goebels. 2003. Clonal tracking of autoaggressive T cells in polymyositis by combining laser microdissection, single-cell PCR, and CDR3-spectratype analysis. *Proc. Natl. Acad. Sci. USA* 100: 4090–4095.
- Lang, H. L., H. Jacobsen, S. Ikemizu, C. Andersson, K. Harlos, L. Madsen, P. Hjorth, L. Sondergaard, A. Svejgaard, K. W. Wucherpfennig, et al. 2002. A functional and structural basis for TCR cross-reactivity in multiple sclerosis. *Nat. Immunol.* 3: 940–943.
- Fredriksson, T., and U. Pettersson. 1978. Severe psoriasis—oral therapy with a new retinoid. *Dermatologica* 157: 238–244.
- Menssen, A., P. Trommler, S. Vollmer, D. Schendel, E. Albert, L. Gürtler, G. Riethmüller, and J. C. Prinz. 1995. Evidence for an antigen-specific cellular immune response in skin lesions of patients with psoriasis vulgaris. *J. Immunol.* 155: 4078–4083.
- Vollmer, S., A. Menssen, and J. C. Prinz. 2001. Dominant lesional T cell receptor rearrangements persist in relapsing psoriasis but are absent from nonlesional skin: evidence for a stable antigen-specific pathogenic T cell response in psoriasis vulgaris. *J. Invest. Dermatol.* 117: 1296–1301.
- Prinz, J. C., S. Vollmer, W.-H. Boehncke, A. Menssen, I. Laisney, and P. Trommler. 1999. Selection of conserved TCR-VDJ-rearrangements in chronic psoriatic plaques indicates a common antigen in psoriasis vulgaris. *Eur. J. Immunol.* 29: 3360–3368.
- Even, J., A. Lim, I. Puisieux, L. Ferradini, P.Y. Dietrich, A. Toubert, T. Hercend, F. Triebel, C. Pannetier, and P. Kourilsky. 1995. T cell repertoires in healthy and diseased human tissue analysed by T cell receptor β -chain CDR3 size determination: evidence for oligoclonal expansions in tumours and inflammatory diseases. *Res. Immunol.* 146: 65–80.
- Pannetier, C., M. Cochet, S. Darche, A. Casrouge, M. Zoller, and P. Kourilsky. 1993. The sizes of the CDR3 hypervariable regions of the murine T cell receptor β -chains vary as function of the recombined germ-line segments. *Proc. Natl. Acad. Sci. USA* 90: 4319–4323.
- Hone, S. W., M. J. Donnelly, F. Powell, and A. W. Blayney. 1996. Clearance of recalcitrant psoriasis after tonsillectomy. *Clin. Otolaryngol.* 21: 546–547.
- Nyfors, A., P. A. Rasmussen, K. Lemholt, and B. Eriksen. 1975. Improvement of refractory psoriasis vulgaris after tonsillectomy. *Dermatologica* 151: 216–222.
- McMillin, B. D., B. R. Maddern, and W. R. Graham. 1999. A role for tonsillectomy in the treatment of psoriasis? *Ear Nose Throat J.* 78: 155–158.
- Chang, J. C. C., L. R. Smith, K. J. Froning, B. J. Schwabe, J. A. Laxer, L. L. Caralli, H. H. Kurland, M. A. Karasek, D. I. Wilkinson, D. J. Carlo, and S. W. Brostoff. 1994. CD8⁺ T cells in psoriatic lesions preferentially use T cell receptor $V\beta 3$ and/or $V\beta 13.1$ genes. *Proc. Natl. Acad. Sci. USA* 91: 9282–9286.
- Chang, J. C., L. R. Smith, K. J. Froning, H. H. Kurland, B. J. Schwabe, K. K. Blumeyer, M. A. Karasek, D. I. Wilkinson, E. M. Farber, D. J. Carlo, and S. W. Brostoff. 1997. Persistence of T cell clones in psoriatic lesions. *Arch. Dermatol.* 133: 703–708.
- Fuhlbrigge, R. C., J. D. Kieffer, D. Armerding, and T. S. Kupper. 1997. Cutaneous lymphocyte antigen is a specialized form of PSGL-1 expressed on skin-homing T cells. *Nature* 389: 978–981.
- Pitzalis, C., A. Cauli, N. Pipitone, C. Smith, J. Barker, A. Marchesoni, G. Yanni, and G. S. Panayi. 1996. Cutaneous lymphocyte antigen-positive T lymphocytes preferentially migrate to the skin but not to the joint in psoriatic arthritis. *Arthritis Rheum.* 39: 137–145.

34. Lew, W., A. M. Bowcock, and J. G. Krueger. 2004. Psoriasis vulgaris: cutaneous lymphoid tissue supports T cell activation and type 1^l inflammatory gene expression. *Trends Immunol.* 25: 295–305.
35. Theofilopoulos, A. N. 1995. The basis of autoimmunity. Part I. Mechanisms of aberrant self-recognition. *Immunol. Today* 16: 90–98.
36. von Boehmer, H. 1994. Positive selection of lymphocytes. *Cell* 76: 219–228.
37. Robey, E., and B. J. Fowlkes. 1994. Selective events in T cell development. *Annu. Rev. Immunol.* 12: 675–705.
38. Sakuma, H., K. Kohyama, Y. Jee, and Y. Matsumoto. 2004. Tracking of V β 8.2-positive encephalitogenic T cells by complementarity-determining region 3 spectratyping and subsequent Southern blot hybridization in Lewis rats after neuroantigen sensitization. *J. Immunol.* 173: 4516–4522.
39. Nozawa, H., K. Kishibe, M. Takahara, and Y. Harabuchi. 2005. Expression of cutaneous lymphocyte-associated antigen (CLA) in tonsillar T cells and its induction by in vitro stimulation with α -streptococci in patients with pustulosis palmaris et plantaris (PPP). *Clin. Immunol.* 116: 42–53.
40. Wagers, A. J., C. M. Waters, L. M. Stoolman, and G. S. Kansas. 1998. Interleukin 12 and interleukin 4 control T cell adhesion to endothelial selectins through opposite effects on α 1,3-fucosyltransferase VII gene expression. *J. Exp. Med.* 188: 2225–2231.
41. Leung, D. Y. M., M. Gately, A. Trumble, B. Ferguson-Darnell, P. M. Schlievert, and L. J. Picker. 1995. Bacterial superantigens induce T cell expression of the skin-selective homing receptor, the cutaneous lymphocyte-associated antigen (CLA). *J. Exp. Med.* 181: 747–753.
42. Leung, D. Y., J. B. Travers, R. Giorno, D. A. Norris, R. Skinner, J. Aelion, L. V. Kazemi, M. H. Kim, A. E. Trumble, M. Kotb, and P. M. Schlievert. 1995. Evidence for a streptococcal superantigen-driven process in acute guttate psoriasis. *J. Clin. Invest.* 96: 2106–2112.
43. Kawano, M., K. Okada, H. Muramoto, H. Morishita, T. Omura, R. Inoue, S. Kitajima, K. Katano, I. Koni, H. Mabuchi, and A. Yachie. 2003. Simultaneous, clonally identical T cell expansion in tonsil and synovium in a patient with rheumatoid arthritis and chronic tonsillitis. *Arthritis Rheum.* 48: 2483–2488.
44. Rock, E. P., P. R. Sibbald, M. M. Davis, and Y. H. Chien. 1994. CDR3 length in antigen-specific immune receptors. *J. Exp. Med.* 179: 323–328.